

## **PAIN ASSESSMENT DURING THE REMOVAL OF INFECTED CARIOUS DENTIN USING CERAMIC BURS WITHOUT LOCAL ANESTHESIA IN CHILDREN**

Moustafa A. Matar\* *and* Rehab Samir\*

### **ABSTRACT**

Negative dental experiences in childhood can lead to dental phobias in adult patients. The dentist's role is to lessen dental anxiety by providing a pain-free procedure. This could be achieved by using painless procedures in caries removal such as air abrasion, laser, chemo-mechanical, enzymatic techniques, as well as the use of polymer or ceramic burs. Ceramic burs are rotary cutting instruments made of alumina-yttria stabilized zirconia round burs. They work by selective removal of carious infected dentin consequently avoiding pain which could be more appropriate for very young children.

The aim of this study was to assess the extent of pain perception using ceramic burs during caries removal without local anesthesia in pediatric patients. This was performed on 51 patients between 4-8 years of age with 2 primary molars showing dentinal caries requiring class I restoration. The first visit (group I) caries was removed by ceramic bur on low speed hand-piece without administration of local anesthesia then the second visit (group II) caries was removed by carbide round bur on low speed hand-piece without administration of local anesthesia. During each procedure, objective assessment for pain was performed using FLACC scale. Upon completion, the pain threshold for caries removal was measured subjectively by Wong Baker faces pain rating scale. The various responses were gathered and subjected to statistical analysis. It was concluded that ceramic burs reduce the pain sensation during removal of infected dentin which ensures excellent patient comfort. There could be some advantages in using the ceramic bur: high acceptance by the patient, reduced pain response and sound pulp protection in deep caries lesions.

### **INTRODUCTION**

Dental procedures are usually associated with the anticipation of pain. This occurs especially with children. <sup>(1)</sup> Pain related to dental treatment has an important role in the etiology of dental anxiety,

whereas this resultant anxiety can increase the amount of perceived pain. <sup>(2)</sup> The pain which is experienced during a dental visit is generally the result of the tissue response to a damaging factor such as tissue inflammation, local anesthesia

\* Lecturer of Pediatric Dentistry, Faculty of Dentistry, Pharos University, Alexandria, Egypt

injection or the use of the high speed handpiece.<sup>(3,4)</sup> As the earlier dental negative experiences shape a subjective memory of pain, which results in a specific response, so it is the dentist's role to alleviate dental anxiety by providing a pain-free procedure.<sup>(1)</sup> This is particularly important in pediatric dentistry, as negative experiences of dental visits in childhood can lead to dental phobias in adult patients.<sup>(2)</sup>

Different reports of pain in dentistry implicated burs when being used without the application of local anesthesia and that a decrease in pain perception can be attained by the appropriate use of local anesthesia.<sup>(5)</sup> In recent years, there has been progress in developing new less invasive painless procedures which are effective in caries removal to replace conventional ones to minimize the loss of sound enamel and dentin. These include air abrasion, laser, chemo-mechanical, enzymatic techniques, as well as the use of polymer or ceramic burs.<sup>(5,6)</sup>

Infected carious dentin is composed of an outer layer of bacteria that is irreversibly denatured and an inner affected layer that is capable of remineralization. Affected carious dentin is valuable as it has low permeability compared with healthy dentin which in turn protects the pulp. Moreover, the odontoblasts precipitate calcium phosphate to form plugs in the dentin tubules, creating the odontoblastic reaction zone. This will lead to caries arrest over periods of up to 10 years.<sup>(7)</sup>

A reliable method of removing only irreversible infected dentin caries with limited and predictable penetration into the reversible affected dentin would be beneficial and considered as an advance in conservative dentistry. A cavity preparation based on selective cutting through carious dentin has developed through the last few years. This approach was coupled with adhesive dentistry materials and techniques. Anusavice and Kincheloe confirmed that cutting through carious dentin generally elicits little or no sensation, while cutting through sound dentin often results in some level of pain.<sup>(8)</sup> The concept of

removing only the infected dentin layer depended on various diagnostic aids, such as the tactile sensation of an explorer, caries detecting dyes and electrical methods.<sup>(6)</sup> However, all methods would lead to highly variable differences in the amount of dentin removed.

Traditional cavity preparations involving the use of carbide or diamond burs and extending into sound dentin are coupled usually with local anesthesia to prevent painful stimuli. They remove reversible affected dentin resulting in exposure of the healthy dentin. Yoshiyama, et al showed that the Knoop hardness of caries-affected dentin is in the range of 10-40 kg/mm<sup>2</sup>, and healthy dentin is in the range of 45-63 kg/mm<sup>2</sup>.<sup>(9)</sup>

Different manufacturers developed new instruments that would act upon selective removal of carious dentin; one of those is the ceramic bur. It has hardness less than that of healthy dentin. It is self-limiting as it is designed to lose its cutting efficiency while in the caries-affected dentin or sound dentin. Dentists can monitor the cutting efficiency easily via the feel of the resistance of the dentin. They are intended for slow-speed caries excavation (CeraBur K1SM, Komet-Brasseler, Lemgo, Germany). They are rotary cutting instruments made of alumina-yttria stabilized zirconia and available in different diameter sizes (10, 14, 18 and 23 mm) round burs.<sup>(10)</sup> Ceramic burs aim on selective removal of carious infected dentin consequently avoiding pain. They could be more appropriate for very young children, in order to reduce the degree of pain experienced during the dental procedures and also to avoid the initiation of dental anxiety. The aim of the present study was to assess the extent of pain perception using ceramic burs during caries removal without local anesthesia in pediatric patients.

## MATERIAL AND METHODS

This randomized study was conducted in the Pediatric Dentistry Department at Pharos University. Full detailed treatment was explained to the parents

of the children and a written informed consent for the treatment was obtained from the parent prior to participation of children in the study.

Fifty one patients aged between 4 and 8 years with 2 primary molars requiring dental restoration were included in the study. Each child had to meet inclusion criteria of having 2 class I carious cavitated teeth on both sides with dentin involvement which was verified on x ray film, showing positive response of each tooth to cold and heat pulp testing, should be clinically free of any pathologic condition other than dental caries, should have at least 2/3 of root length present and either first or second primary molar. Molars with any of the following criteria were excluded from the study: teeth showing clinical or radiographic signs of irreversible pulpitis and its sequelae, teeth with pathological conditions such as dental erosions or tooth developmental disorders and carious lesions extending proximally excluded by the x-ray. The sample was assigned in the first visit to group I in which, caries was removed by ceramic bur on low speed hand-piece without administration of local anesthesia then the following visit the sample became in group II, in which, caries was removed by carbide round bur on low speed hand-piece without administration of local anesthesia. Material used: Ceramic burs (CeraBur K1SM, Komet-Brasseler, Lemgo, Germany), low speed Hand-piece, carbide round bur number 2, and a restorative material.

**Clinical procedure:** Each child had their teeth dried and visually examined using dental mirror and probe, and two primary molars with dentinal caries (Class I) were chosen for treatment. X-ray was taken to fulfil all inclusion criteria and to exclude caries in proximal surfaces. No anesthetic solution was used before starting the procedure for the purpose of the study and for objective assessment of pain perception. The patient was informed that in case there is discomfort or pain, he has the choice of being anesthetized. In group I, using ceramic burs on low

speed hand-piece with adequate coolant, infected carious dentin was removed leaving the affected dentin as recommended by the manufacturer. In group II, using carbide round bur on low speed hand-piece, infected and affected carious dentin were removed. The efficacy of caries removal was checked using an explorer so it should not stick to dentin, and not giving a tug-back sensation. During each procedure, objective assessment for pain was done by the dentist using FLACC scale (fig.1).<sup>(11)</sup> The dentist was observing face, legs, activity, cry and consolability on a scale of 0 to 3 rating from least to most.

| Category             | Scoring                                      |  |   |
|----------------------|--|--|---|
|                      | 1  | 2  | 3   |
| <b>Face</b>          | No particular expression or smile            | Occasional grimace or frown, withdrawn, disinterested                      | Frequent to constant quivering chin, clenched jaw     |
| <b>Legs</b>          | Normal position or relaxed                   | Uneasy, restless, tense  | Kicking, or legs drawn up                             |
| <b>Activity</b>      | Lying quietly, normal position, moves easily | Squirming, shifting back and forth, tense                                  | Arched, rigid or jerking                              |
| <b>Cry</b>           | No cry (awake or asleep)                     | Moans or whimpers; occasional complaint                                    | Crying steadily, screams or sobs, frequent complaints |
| <b>Consolability</b> | Content, relaxed                             | Reassured by occasional touching, hugging or being talked to, distractible | Difficult to console or comfort                       |

Fig. (1) Face, legs, activity, cry and consolability scale

Once the clinical procedure was completed, the pain threshold of caries removal was measured subjectively by Wong Baker faces pain rating scale (fig.2).<sup>(12)</sup> The child was asked to rate the pain and discomfort on a 6 point scale, with a smiling child at one end and a tearful child at the other. (0 – no hurt, 1 – hurts little bit, 2 – hurts little more, 3 – hurts even more, 4 – hurts whole lot, 5 - hurts worst). The selected face was taken as the pain score. At the end of the study, the cavity was restored using an appropriate restorative material. The various responses were gathered and subjected to statistical analysis. The statistical analysis was performed using the SPSS program (v. 20.0, SPSS Inc., Chicago, IL, USA) with the level of significance set to 5% ( $P < 0.05$ ).

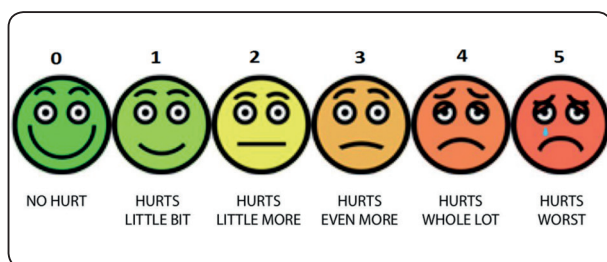


Fig. (2) Wong Baker faces pain rating scale.

**RESULTS:**

Ceramic bur group showed a significant decrease ( $P < 0.001$ ) in the discomfort level when reported by the patients compared with the carbide bur group as shown in table 1. Ceramic bur group recorded the least rating of pain (mild discomfort) observed by the examiner which was statistically significant compared with the carbide bur as shown in table 2.

TABLE (1): Comparison between both groups regarding patients' response to pain using the Wong Baker faces pain rating scale

|                   | The percentages of each score of Wong Baker faces pain rating scale |             |             |             |             |             |
|-------------------|---|-------------|-------------|-------------|-------------|-------------|
|                   | Score 0 (%)   | Score 1 (%) | Score 2 (%) | Score 3 (%) | Score 4 (%) | Score 5 (%) |
| Group I (n = 51)  | 52.9  | 17.6        | 17.6        | 5.9         | 5.9         | 0           |
| Group II (n = 51) | 5.9   | 11.8        | 17.6        | 17.6        | 29.4        | 17.6        |
| $\chi^2$          | 39.800*   |             |             |             |             |             |
| P                 | <0.001*   |             |             |             |             |             |

$\chi^2$ : Chi square test

\*: Statistically significant at  $p \leq 0.05$

TABLE (2): Comparison between both groups regarding the dentist assessment of behavioral response of the child using FLACC scale.

| The percentage of different behavioral response according to FLACC scale | Group I (n = 51) | Group II (n = 51) | $\chi^2$ | p       |
|--|------------------|-------------------|----------|---------|
|  | %                | %                 |          |         |
| Relaxed and comfortable (0)  | 0.0              | 0.0               | 34.749*  | <0.001* |
| Mild discomfort (1-3)  | 76.5             | 23.5              |          |         |
| Moderate pain (4-6)  | 23.5             | 41.2              |          |         |
| Severe discomfort or pain or both (7-10)                                 | 0.0              | 35.3              |          |         |

$\chi^2$ : Chi square test

\*: Statistically significant at  $p \leq 0.05$

## DISCUSSION

Out of all dental procedures the highest anxiety level was created by treating of dental caries and that dental fear could be alleviated by painless treatment. <sup>(13)</sup> Moreover, Anusavice et al<sup>(8)</sup> stressed on that there was a need to reduce the use of local analgesia in most dental procedures. Carbide bur when used to remove dentinal caries can remove both infected and affected dentin simultaneously, thereby opening more dentinal tubules. This can cause pain and may necessitate the need for local anesthesia. <sup>(14)</sup> Few studies have focused on the child behavior during caries removal. <sup>(15)</sup> Hence, in the present study, the aim was to evaluate the pain reaction to two different methods of caries excavation in children aged 4-8 years.

Patients' ability to cope with stressful situations should not be limited to the use of pharmacological techniques. <sup>(16)</sup> Consequently, searching for new painless methods for treating dental caries as a method of eliminating pain and anxiety within the dental visits is necessary. Successful dental treatment in a child depends not only on the treatment itself, but also in instilling a positive attitude toward dental care later on. In light of minimal-invasive dentistry 'self-limiting' caries-excitation techniques have been introduced which is claimed to elicit less pain perception. <sup>(6)</sup>

The Wong Baker faces pain rating scale used in this study has been proven to be a reasonable and valid scale for measuring subjectively the degree of experienced pain in children. <sup>(12)</sup> The other scale used, the FLACC scale, also has been proven to be a valid scale for measuring objectively the degree of exhibited pain. <sup>(11)</sup>

The findings in the current study revealed that using ceramic bur in excavating dentin caries produced least experienced pain compared to using carbide bur. In the study conducted by Bergmann et al. <sup>(17)</sup> it was shown that conventional carbide bur group had more discomfort when compared to the carisolv group during caries

removal procedure in children. FLACC scale also suggested that using carbide bur produced more pain than ceramic bur probably cutting and opening the dentinal tubules is responsible for this outcome.

Based on the results of the present study, it can be concluded that ceramic burs reduce the pain sensation during removal of infected dentin ensured excellent patient comfort. It is recommended further investigations are necessary to determine the difference between ceramic burs and other minimal invasive methods. Studies with increased sample size could give an image of the behavioral response of children to caries management which could in turn help in preventing avoidance of dental health care. Finally, it is evident that there could be some advantages when using the ceramic bur which are: high acceptance by the patient, reduced pain response and sound pulp protection in deep caries lesions.

## REFERENCES

1. Kobierska A. Sources of dental fear in patients. (Polish). *Czas Stomatol*, 1996;48:606-610.
2. Rhudy JL, Meagher MW. Fear and anxiety: divergent effects on human pain thresholds. *Pain* 2000; 84: 65-75.
3. Keogh E, Ellery D, Hunt C, Hannent I. Selective attentional bias for pain-related stimuli amongst pain fearful individuals. *Pain* 2001; 91: 91-100.
4. Zvolensky MJ, Goodie JL, McNeil DW, Sperry JA, Sorrel JT. Anxiety sensitivity in the prediction of pain-related fear and anxiety in a heterogeneous chronic pain population. *Behav Res Ther* 2001; 39: 683-696.
5. Maragakis GM, Hahn P, Hellwig E. Clinical evaluation of chemomechanical caries removal in primary molars and its acceptance by patients. *Caries Res* 2001;35:205-210
6. Tassery H, Levallois B, Terrer E, Manton DJ, Otsuki M, Koubi S, Gugnani N, Panayotov I, Jacquot B, Cuisinier F, Rechmann P. Use of new minimum intervention dentistry technologies in caries management. *Australian Dental Journal* 2013; 58:(1 Suppl): 40-59
7. Van Thompson, Craig RG, Curro FA, Green WS, Ship JA. Treatment of deep carious lesions by complete excavation or partial removal: A critical review. *J Am Dent Assoc*. 2008 Jun; 139(6): 705-712.

8. Anusavice KJ, Kincheloe JE. Comparison of pain associated with mechanical and chemomechanical removal of caries. *J Dent Res.* 1987 Nov;66(11):1680-3
9. Moron B.M.a · Comar L.P.a · Wiegand A.b · Buchalla W.b · Yu H.b, c · Buzalaf M.A.R.a · Magalhães AC. Different Protocols to Produce Artificial Dentine Carious Lesions in vitro and in situ: Hardness and Mineral Content Correlation. *Caries Res* 2013;47:162–170
10. Dammaschke T, Vesnic A, Schäfer E. In vitro comparison of ceramic burs and conventional tungsten carbide bud burs in dentin caries excavation. *Quintessence Int* 2008;39:495-499
11. Merkel SI, Voepel-Lewis T, Shayevitz JR, Malviya S. The FLACC: a behavioral scale for scoring postoperative pain in young children. *Pediatr Nurs* 1997;23:293–7.
12. Wong DL, Baker C. Pain in children: comparison of assessment scales. *Pediatr Nurs* 1988;14:9–17.
13. Klingberg G, Broberg AG. Dental fear/anxiety and dental behaviour management problems in children and adolescents: a review of prevalence and concomitant psychological factors. *Int J Paediatr Dent.* 2007; 17: 391- 406.
14. Kotb RM, Abdella AA, El Kateb MA, Ahmed AM. Clinical evaluation of Papacarie in primary teeth. *J Clin Pediatr Dent* 2009;34:117-23.
15. Chomyszyn-Gajewska M, Kwapinska H, Zarzecka J. Pain perception in children during caries removal with the Vector system: a pilot study. *Eur Arch Paediatr Dent.* 2006 Mar;7(1):38-41.
16. Frączak B., Ey-Chmielewska H, Gorzkowski G. Fear and methods of overcoming it in dental patients. (Polish). *Czas Stomatol*, 1994;47:643-645.
17. Bergmann J, Leitão J, Kultje C, Bergmann D, Clode MJ. Removing dentine caries in deciduous teeth with Carisolv: A randomised, controlled, prospective study with six-month follow-up, comparing chemomechanical treatment with drilling. *Oral Health Prev Dent* 2005;3:105-11